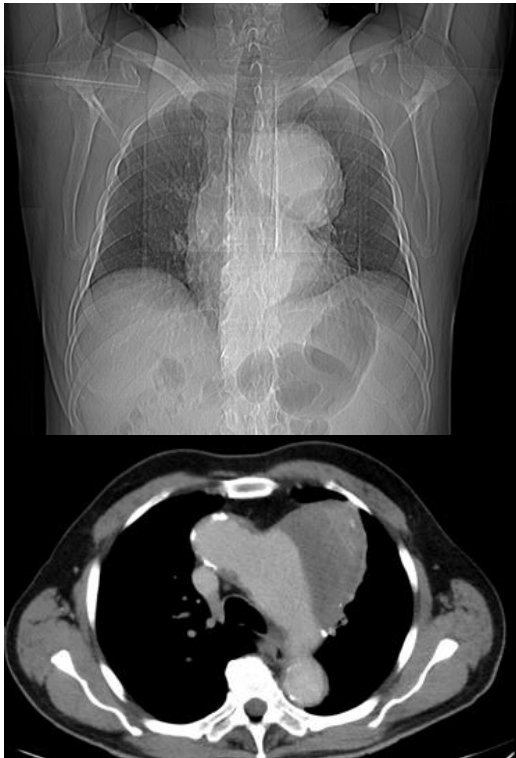


Clinical update no. 528

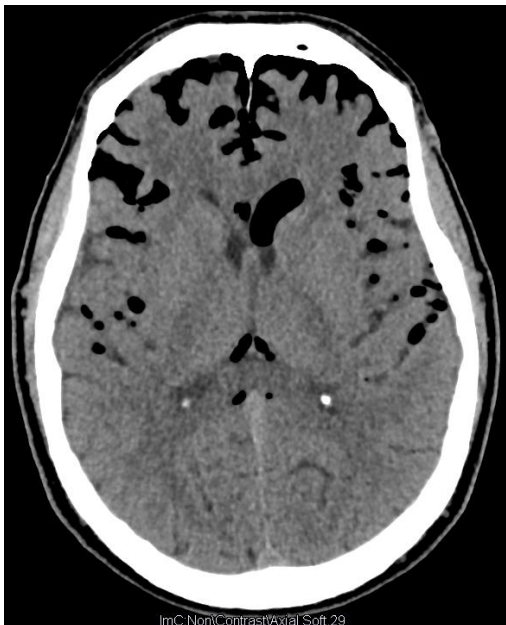9 January 2019

71yr-M, investigated by GP for hoarse voice.

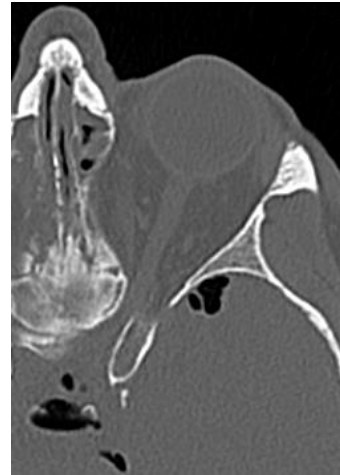

Aortic dissection with surrounding haematoma, and likely compression of recurrent laryngeal n. – they can be chronic.

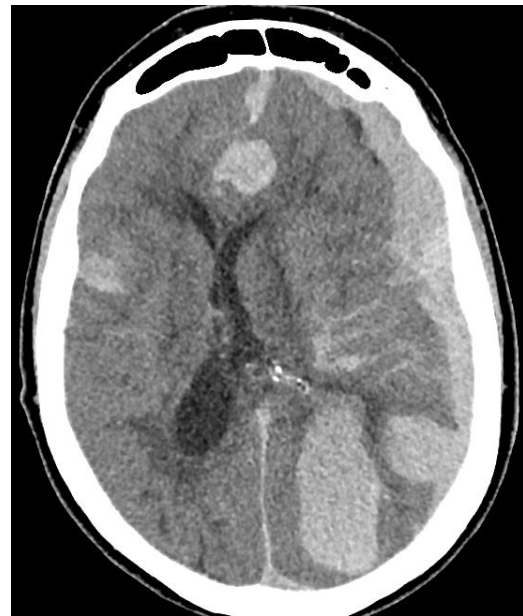58yr-F. Headache and nasal drip after orbital decompression done for proptosis from Grave's disease. Defects up to 9mm in cribriform plate.



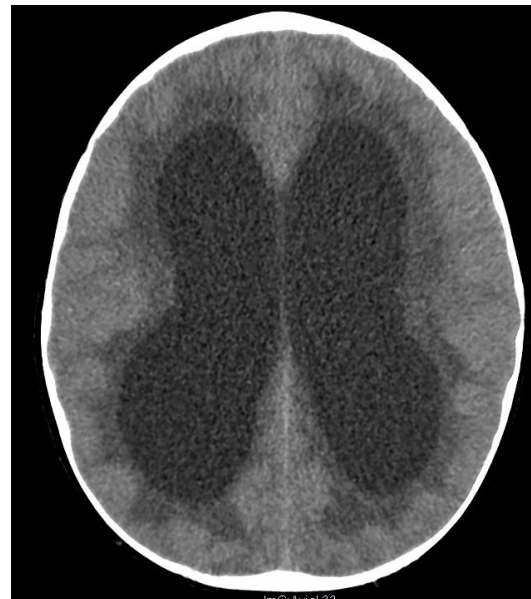ImC:NoniContrastAxial Soft 29



Post thrombolysis for stroke.



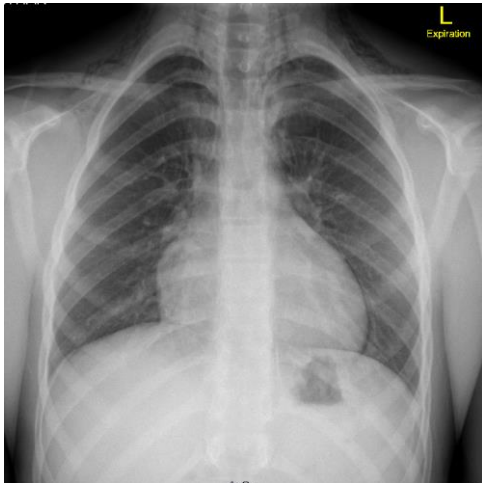
7yr-M with concern for drowsiness, incoordination and unsteady on feet



ImC:Axial 43

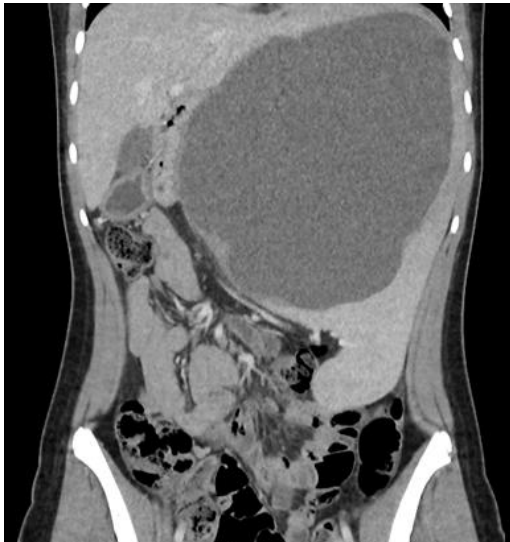Underlying glioma giving CSF outflow obstruction. Improved after ventriculostomy with good recovery to normal activity and function.

14yr boy, heavy tackle at football and player landed on chest. Finished game, subsequent breathing difficulty which resolved and asymptomatic, normal vitals when seen.



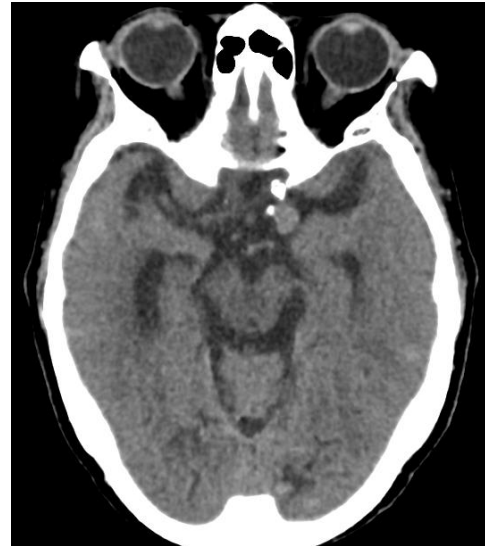Pneumomediastinum, with subcutaneous emphysema. Remained asymptomatic. High flow O2 given to facilitate resorption of N2 from the tissues.

17yr-F presented with unrelated complaint, described abdominal fullness.

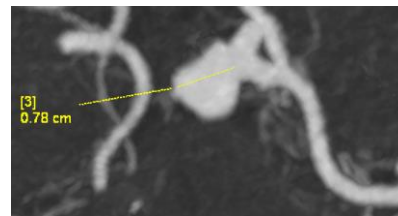


2 litres drained from a splenic dermoid cyst.

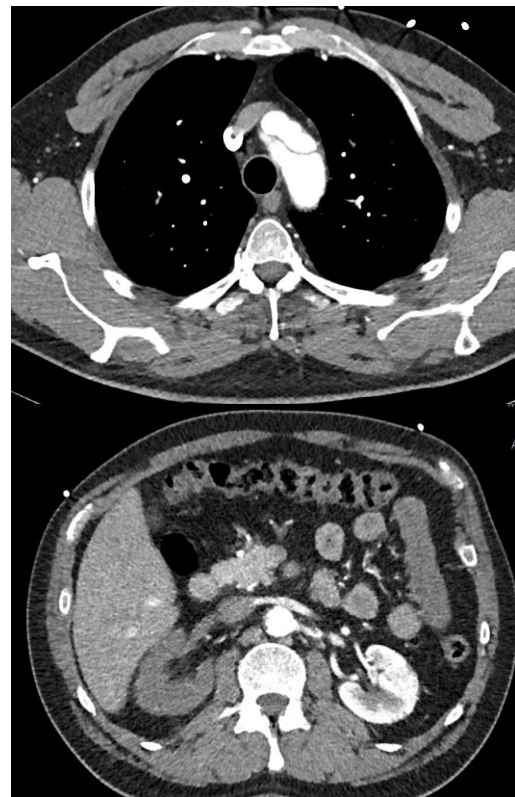78yr-F with vomiting and headache attributed to gastro. Continued symptoms and represented 7 days later.



9mm aneurysm seen on non contrast CT.



35yr-M, sudden onset umbilical pain with numbness down right leg.



Type A thoracic aortic dissection from arch to ileac art extending into carotid art with lack of perfusion right kidney. Can happen young.